

Cataract & Refractive Surgery

EUROPE


TODAY

LENTIS *Mplus*

and

LENTIS *Mplus*^{toric}

Advanced multifocal
IOL technology for the
treatment of presbyopia,
astigmatism, and cataract.



LENTIS Mplus and LENTIS Mplus Toric

Advanced multifocal IOL technology for the treatment of presbyopia, astigmatism, and cataract.

MODERATORS



Detlev R.H. Breyer, MD, is Head of Breyer Eye Surgery, a private practice and day clinic in Düsseldorf, Germany, and is a Senior Consultant to Marien Hospital in Düsseldorf, Germany. Dr. Breyer states that he has no financial interest in the products or companies mentioned. He may be reached at tel: +49 211 5867 5726; e-mail: d.breyer@breyer-augenchirurgie.de.



Claudio Carbonara, MD, practices at the Carbonara Eye Center and performs surgery at the Primavista Eye Surgery Center, both in Rome. Dr. Carbonara states that he has no financial interest in the products or companies mentioned. He may be reached at e-mail: carbo-eye@iol.it.



Erik L. Mertens, MD, FEBOphth, is Medical Director of Medipolis, Antwerp, Belgium. Dr. Mertens states that he is a consultant to Topcon. He may be reached at tel: +32 3 828 29 49; e-mail: e.mertens@medipolis.be.



Anders Granberg, MD, is a Medical Director. Dr. Granberg did not provide financial disclosure information. He may be reached at e-mail: anders.granberg@memira.se.



Johnny Moore, MD, PhD, is the Medical Director, Cathedral Eye Clinic and a Consultant in anterior segment, cataract, and refractive surgery at Royal Victoria Hospital Belfast, both in the United Kingdom. Dr. Moore states that he is a consultant to Topcon. He may be reached at e-mail: johnnymoorebal@googlemail.com.

PARTICIPANTS



Jaime Aramberri, MD, practices at the Begitek Ophthalmology Clinic, San Sebastian, Spain, and the Okular Ophthalmology Clinic, Vitoria, Spain. Dr. Aramberri states that he has no financial interest in the products or companies mentioned. He may be reached at e-mail: jaimearamberri@telefonica.net.



Dominique Pietrini, MD, practices at the Clinique de la Vision, Paris. Dr. Pietrini states that he has no financial interest in the products or companies mentioned. He may be reached at tel: +33 1 58 05 2000; fax: +33 1 58 05 2001; e-mail: dpietrini@club.fr.



Gerd U. Auffarth, MD, FEBOphth, is Chairman of the Department of Ophthalmology, University of Heidelberg, Germany. Professor Auffarth states that he has performed contract research for Oculentis. He may be reached at e-mail: ga@uni-hd.de.

Jan A. Venter, MD, is the Medical Director for Optical Express. Dr. Venter states that he has no financial interest in the products or companies mentioned. He may be reached at e-mail: drjanventer@googlemail.com.



Edmondo Borasio, MedCBQ Ophth, FEBO, is a Consultant in cataract, corneal, and refractive surgery at Moorfields Eye Hospital, Dubai, UAE. Dr. Borasio states that he is a paid consultant to Oculentis and a shareholder of EB EYE Ltd, producer of Eye Pro and the BESSt IOL Power Calculator. He may be reached at tel: +971 4 4297888; fax: +971 4 363 5339; e-mail: dr@edmondoborasio.com.

Oculentis GmbH recently invited a panel of world-renowned surgeons to convene for a discussion on the LENTIS Mplus and LENTIS Mplus Toric IOLs. These lenses are both presbyopia-correcting, multifocal IOLs with a refractive design; however, they represent a completely new approach in multifocal lens technology due to each of the lenses' innovative sector-shaped near vision section (Figure 1), providing HD-vision-natural contrast sensitivity, no image jumps, and excellent distance and near BCVA.

TALKING POINT NO. 1: PRESBYOPIC LENS EXCHANGE

Breyer: The reason that we are gathered together is because we all agree that Oculentis' LENTIS Mplus and Mplus Toric IOLs are wonderful new products. We all have implanted these lenses in our patients—some of us have implanted hundreds while others of us are in the beginning stages and are still learning what this lens can do. The fact that we have such a diverse range of experience among us today will make this roundtable very lively. I am sure we will all walk away from this discussion having learned something new.

I would like to begin by talking about the treatment of presbyopia and astigmatism. Specifically, how many of you are doing routine presbyopic lens exchange, and if you are, how many of those IOLs are you exchanging for the Mplus?

Aramberri: My practice is mainly a refractive surgery practice, and I have been implanting the Mplus as a lens-based refractive option since 2009. Although I do perform refractive lens surgery, I will not perform presbyopic lens exchange except in the definition of emmetropic surgery. I normally will not perform refractive lens surgery in emmetropes, as I prefer to treat patients with previous refractions. This consists mainly of hyperopes, but I also treat some myopes as well as patients who are between the ages of 50 and 55 years old. I might do some emmetropes mainly after 60 years old, and right now I have to say that the lens I use most is the Mplus.

Breyer: I have had the experience that hyperopic patients turn out to be a little bit on the hyperopic side after surgery. Therefore, I target slight myopia. Let me explain: If you implant a Mplus Toric in a hyperopic patient, their refraction will end up closer to 0.25 D. To compensate, I aim for a refractive target of -0.25 to -0.50 D instead of plano. Has anyone else seen this?

Aramberri: It depends on how you perform your calculations. I do ray tracing, using my own model first and then checking the results against the regular formulas. I do not have the radius or thickness data for this lens, so I calculated the IOL power using data from another modern lens and added the difference in the A-constant of these lenses. This seems to have worked, as our refractive results with the Mplus have been excellent thus far. I can tell you that, right

now, my rate for retreatment after IOL implantation with the Mplus is below 5%. As we are on target in more than 95% of our cases, I feel that this eludes to the fact that we are doing it correctly.

What we must remember is that this kind of patient is aiming for real emmetropia. Anything above a difference of 0.50 D from the target refraction, and the patient will need a laser enhancement.



Figure 1. The Mplus Toric IOL. The lens' sector-shaped near vision segment enhances contrast sensitivity.

Granberg: I am a medical director in Sweden. We have 24 clinics across the country, and we mainly do laser vision correction and refractive lens exchange procedures. We do presbyopic lens exchange on most of our patients. We have done some emmetropes, but we have a very careful patient selection process in this population.

We started implanting the Mplus in October 2010. To date, we have implanted this lens in more than 2,000 eyes. We then started with the Mplus Toric in February 2011 and have already implanted this lens in approximately 350 eyes. The main feeling across our centers is that the Mplus and the Mplus Toric are really good lenses. We have no *buts* anymore; there simply are not the side effects we have seen with other multifocal IOLs. We used to mix-and-match the AcrySof ReStor (Alcon Laboratories, Inc.) with another IOL, and the results were favorable. But now that we are using the Mplus, we are even more confident in our results.

Breyer: It sounds as if you have completely shifted from the ReStor to the Mplus. Do you see any indications for the ReStor?

Granberg: No. I was not satisfied with the outcomes using the ReStor, as you had to mix-and-match. However, it was the best available option until the Mplus entered the market.

Breyer: When a patient wants very good near vision after lens implantation, I previously chose the AT.LISA (Carl Zeiss Meditec) or the Tecnis Multifocal (Abbott Medical Optics Inc.). This may begin to change now that the Mplus is in my rotation. Do you think that these and other multifocal IOLs can compete with the Mplus?

Granberg: No, and that is why we have changed com-

LENTIS Mplus and LENTIS Mplus Toric

pletely to the Mplus. This lens is pupil independent, and therefore patients have fewer problems with night vision. Of course there are still a small number of patients who complain of these problems, but, in the majority of cases, patients are satisfied.

Carbonara: I practice in a private eye surgery center in Rome. I prefer not to perform refractive lens exchange; however, in some cases when the refractive error is very high, I will do it. In my everyday practice, I have changed completely from implanting the AcrySof ReStor to the Mplus, or to the Mplus Toric when appropriate. I have been impressed with both designs, and my patients have had a high satisfaction rate with both models. They provide good distance and near vision, even after 1 day after surgery. Therefore, I have stopped implanting any other type of multifocal IOL.

Borasio: I practice at Moorfields Eye Hospital in Dubai. I have to say that, generally speaking, I have never been a strong supporter of multifocal technology because of the issues with contrast sensitivity and reduced image quality. Only when I heard good reports about the Mplus from colleagues of mine did I become curious; I really wanted to see how this concept of bifocal multifocality would work. So far with the Mplus, I have had happy patients. They often come back with big smiles—more than what I am seeing after monofocal IOL implantation. Therefore, I am moving forward to implant these lenses more often, and I am expanding my range of corrections.

We do offer presbyopic refractive lens exchange regardless of the patient's refractive error. We would implant the Mplus in emmetropic patients who wish for spectacle independence as long as they have some degree of lenticular opacity. I do not do clear lens extraction in emmetropic eyes with a clear crystalline lens.

Breyer: Will you do it on higher myopes? In my experience, patients from Dubai often have extremely long eyes.

Borasio: I have done some very high myopes with good results. The main problem with treating patients with high myopia is their high expectations.

Venter: There are 40 Optical Express clinics in the United Kingdom, and each clinic performs laser vision correction as well as refractive lens exchange/cataract procedures. We have used many different multifocal IOLs including the Tecnis, AcrySof IQ ReStor, and the AT.LISA, and to date we have done more than 10,000 Mplus implants and in excess of 500 Mplus Toric implants. During the patient counseling process, which is performed by an optometrist, we currently counsel all patients on the Mplus lens. Ninety-five percent of all patients who are treated at one of our centers will receive the Mplus. It is only in patients who have a contraindication, such as macular degeneration or severe

amblyopia, that we won't use the Mplus. We have so much confidence in the Mplus that the surgeon sees the patient on the day of surgery for the first time.

We started implanting this lens in December 2009. Of the 10,000 eyes we have implanted, we have results for 8,000. Of these, 90% are implanted in myopic or hyperopic patients with clear lenses, but we will not do clear lens exchange in plano or emmetropic patients.

According to our results, 80% of patients achieved 20/20 or better UCVA, and 91% achieved 20/40 or better near UCVA. Additionally, 70% were within ± 0.50 D of emmetropia, and only 6% of patients complained of significant night-driving problems.

Pietrini: I work in a private refractive center in Paris, and I do mainly refractive surgery. My approach is perhaps a bit different from the other panelists, because I tend to perform laser surgery to correct presbyopia. As I see it, presbyopic lens exchange is mainly for patients older than 55 or 60 years of age, when laser surgery is no longer indicated.

I have tried other diffractive multifocal lenses for the correction of astigmatism in the past with very good results. But, what is lost for the patient is intermediate vision. When I moved to implanting the Mplus, I found a real improvement in terms of intermediate vision for the patient. There were no more complaints of night vision problems, which my patients frequently complained of with the other multifocal IOLs. Therefore, I have shifted treatment of presbyopia in all my refractive cases to the Mplus Toric for the correction of astigmatism.

Moore: I work in both a University hospital practice and a private practice setting in Belfast. I have implanted Mplus IOLs in approximately 700 patients. The majority of these patients have been myopic, hyperopic, and astigmatic presbyopes. Unlike Dr. Venter, I do use the Mplus in emmetropic presbyopes; however, in these cases, I tend to treat only the nondominant eye. I have found this approach to be useful, although adaptation to glare does take longer than it does in patients who have two eyes treated. We routinely assess each patient with our validated subjective quality of vision questionnaire. This way we are able to carefully follow both the initial induced level of dysphotopsia and the overall quality of vision, as well as the patient's ability to nearadapt to the IOL. We are finding it is a useful method to assess and compare between patients and between IOLs.

I do not do presbyopic laser treatments other than micro-monovision laser vision correction in those patients averse to any form of intraocular treatment. I am considering commencing the use of the Schwind laser presbyopic approach, which is relatively gentle on the cornea by combining micro-monovision and modifications of higher-order aberrations.

Auffarth: I have to say that, of all the multifocal toric

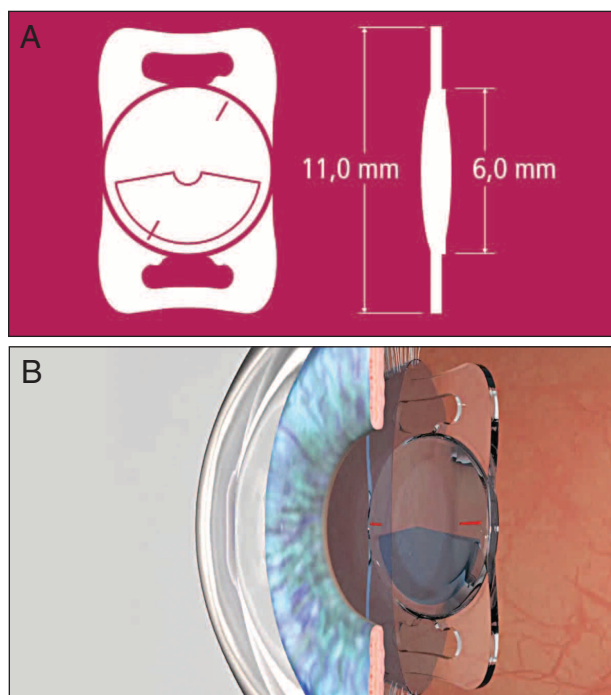


Figure 2. (A) The optic of the LENTIS Mplus is 6 mm; the total diameter of the IOL is 11 mm. (B) The LENTIS Mplus is stable in the capsular bag.

IOLs on the market, the best experience we have had has been with the Mplus Toric. The loss of light is the lowest among all of the multifocal lenses, and the accuracy of the IOL manufacturing is excellent. Another good thing about the Mplus Toric is that the lens is always implanted in the same position; there is no need to rotate the lens toward the axis of astigmatism. You just implant it at the 12-o'clock position (90°), and it always fits well in the eye. I have yet to see a case in which the lens decenters, and this is much more than I can say for competing lenses from other companies.

We perform many kinds of presbyopia treatments, and although we tend to use Intracor or Supracor for patients with emmetropia, I have no problem implanting the Mplus in emmetropes.

TALKING POINT NO. 2: NEAR-VISION SEGMENT

Breyer: This is an impressive roundtable thus far. Many of us here are high-volume surgeons who have transitioned to the LENTIS Mplus from other IOL technologies. We all understand that the LENTIS Mplus incorporates a new optical concept (Figure 2A). Its optical rotation is asymmetrical, with the shape of the near-vision segment providing seamless transitions between near and far vision zones. In your experiences, is this design only an advantage or is there also a disadvantage? Is your surgical planning with this new design based on pupil size and decentration?

Aramberri: Surgeons mainly talk about empiric results—

but a lens either works or it does not. The first time I heard about the Mplus was in early 2009, just as the European trials began. At that time, I really could not tell if this lens was going to work, but I feared that it would induce coma and affect visual quality. Some of my colleagues were trying the lens, and it worked for them.

Since my first implantation, I realized that the Mplus did not affect contrast sensitivity, and it also improved patients' visual quality. I have implanted thousands of lenses and experimented with many designs, but I quickly realized from the first patient that this perception of vision loss was not there. Patients were seeing 20/20 on the first day after surgery. The only matter remaining in some cases was not enough near focal plane. I have shifted completely to this lens design.

Breyer: Have you seen any drawbacks?

Aramberri: The Mplus is pupil independent—this is an advantage—but because the near-vision sector is asymmetric, it demands perfect pupil centration. If this lens becomes decentered, visual symptoms will result, but centration with a diffractive optic is less sensitive. If the diffractive optic becomes decentered, the visual impact is not as apparent.

Moore: Early symptoms of dysphotopsia in some patients prompted me to assess the use of the IOL with the near segment implanted in a superior position. Overall, this seemed to slightly reduce early dysphotopsic symptoms, but it had no long-term advantage. It did produce a small number of cases in which near vision was poor. Several of these patients responded well when the IOL was rotated to position the near segment inferiorly.

Breyer: Jamie, have you changed anything in your preoperative examination to look at the pupil shift?

Aramberri: I have, but not because of what I just said. I cannot predict the relative centration of the capsular bag with respect to the pupil in advance; I can only tell that once the lens is implanted. In patients with small pupils, however, the pupil occludes the inferior segment, limiting exposure of the area that provides near vision. Therefore, we will not implant the Mplus in patients with a pupil smaller than 3.5 mm. Pupillometry, in return, has become more relevant with this lens than with previous lenses.

Venter: Most of our patients are between 40 and 60 years old and are refractive lens exchange patients who happen to have very high expectations. Therefore, we do look at pupil size, and we give every patient a questionnaire that they must answer at 1, 3, and 12 months following surgery. What we have found is that pupils larger than 7 mm have an increased incidence in glare. Therefore, we do not use the 3.00 D add in a pupil that is more than 7 mm; we will use

LENTIS Mplus and LENTIS Mplus Toric

the 1.50 D add lens. I think that is really helpful in managing those patients.

Granberg: I am not as concerned with pupil size. We started implanting the lens shortly after learning about it at the European Society of Cataract and Refractive Surgeons (ESCRS) meeting in Paris in 2010, and we have seen really no drawbacks. I was skeptical at first when I saw the design, but it works. However, we have some patients with unexpected glare or halos that we can't explain.

Aramberri: This is usually a result of decentration.

Granberg: That is what I suspect, as we have not been overly concerned with pupil size. Our cutoff for implantation is a pupil size of 2.5 mm or smaller.

Aramberri: I have to say that this phenomenon was more frequent with the previous platform (312) than it is with the new platform (313). The 313 has improved stability and centration through postoperative long-term results. In my experience, after 1 year of only implanting the 313, I have seen not one case of symptomatic IOL decentration.

Moore: I agree that the new platform enhances results, both in long-term stability and even early visual recovery. Whether the early visual recovery is also related to an overall improved IOL stability, I am unsure.

Carbonara: I routinely implant a capsular tension ring (CTR), so I have not seen any tilting with the Mplus. But my numbers are not as big as the numbers the other surgeons in this room have had. Decentration is not the largest issue here. What is really important is that there are no cases of posterior capsular opacification (PCO) after implantation of the Mplus, which in comparison is very frequent with the AcrySof ReStor. This is one of the reasons why I am satisfied with this Mplus lens. I have even operated on two young ladies with cataract and high myopia who normally wore contact lenses. I was doubtful that they would be satisfied with their near vision after surgery; we all know how good the near vision is in high myopes. These two patients were happy, and they reported good vision with the laptop and did quite well with desktop computers. Although their vision becomes a bit blurry when they are 1 m away from the monitor, for all the other daily activities they are absolutely happy. Additionally, I prefer not to implant this lens if the pupil is too small, which for me is anything smaller than 2.5 mm.

Breyer: I also feel that there is a need for pupillometry and documentation of pupil shift in relation to the visual axis before surgery. An excellent and easy-to-use tool for this purpose is the KR-1W aberrometer from Topcon. Therefore, if there are small problems after surgery we have the documentation of pupillary parameters and are able to learn

from these data to better understand and meet patients' needs in the future.

Auffarth: Those patients who typically receive an Mplus IOL are looking for presbyopia treatment, and therefore they are usually grouped as refractive patients. We always perform pupillometry before any type of refractive surgery; for a cataract patient, however, I would not do pupillometry. The average pupil size for a 70- to 80-year-old patient is 3.5 mm, which is more than sufficient for this lens. Below that age, the pupil is even larger.

I would also like to address the problem with centration, which is the same for every kind of multifocal lens. If you have a 1- to 2-mm decentration, even the Tecnis or the ReStor will give you some problems, especially if you are implanting the toric version. For this reason, I would not over-emphasize the use of pupillometry. If you have a glaucoma patient with a 1.5-mm pupil, there will always be a problem, but those patients are contraindicated.

A refractive patient needs a complete exam, and this includes pupillometry, but I would not say that the lens demands this.

TALKING POINT NO. 3: IMPLANTATION, LENS POSITION

Borasio: The optical properties of this asymmetric multifocal lens are still to be completely understood. It would be interesting to find out whether this near vision sector has to be that big. If it could be smaller, for example, we might be able to reduce the incidence of glare even more. I also wonder if this segment must be located inferiorly. Has anyone tried to shift it? I was thinking that fewer halos and less glare might result if this segment was positioned on the temporal side. When the light comes from the temporal side, it does not hit the temporal side, and when it comes from the nasal side, it hits it less because of the nose in between. It would be interesting to have comparative studies with different positions of the additional sector.

Venter: We have implanted the plate-haptic lens design upside down, and we have seen significant improvements in the lens' performance. We have also implanted it horizontally with good results. Both placements have minimized the incidence of halos and glare.

Borasio: Do you always implant the lens upside down?

Venter: No, but if the patient has excessive glare I will go back in and rotate the lens into an upside down position.

Borasio: Why not just implant it upside down from the start, then?

Venter: You can. And the reading will be the same.

Borasio: And temporally? Have you tried that as well?




Figure 3. Luminous efficiency on optical bench for the M-Flex, ReZoom, Tecnis, and LENTIS Mplus IOLs. Both refractive lenses (M-Flex and ReZoom) show diffuse foci compared to the diffractive (Tecnis) or segment (Mplus) model with two defined foci for near and distance vision.




Figure 4. Lens optical images, rings, or segment. Comparing the screen images of the three multifocal concepts, the Mplus segment lens (bottom right) shows less loss of light than the refractive (ReZoom and M-Flex) or diffractive (Tecnis) lenses.

Venter: Yes, and these patients will have good near (reading) vision as well. However, with the C-loop design we have seen some loss of reading vision, and I think that might be because the lens does not center that well. (We do not use CTRs.)

Moore: I have found a small number of patients with poor or no near vision when the near segment is placed superiorly; however, they have responded well to rotation to an inferior position. In each case, the patient had small pupils (less than or equal to 3 mm) and had a pronounced inferior nasal shift with the near synkinesis.

Aramberri: IOL decentration with the C-loop design may be causative of loss of vision. In many cases, once you have centered the lens, it does not matter if it is oblique; the visual function remains more or less the same. Another application of this asymmetric optic is to compensate for preexisting corneal coma. In cases with a mild keratoconic pattern, I might implant the lens upside down to compensate for the coma. In these cases, I am not looking for presbyopic correction but for visual function improvement.

Breyer: Very interesting point. (Editor's Note: After this roundtable discussion took place, Dr. Breyer said that he completely changed to implanting the Mplus upside down, with good results. He said that patients complain even less of halos and glare.)

Pietrini: The shape of the addition is quite surprising, but the results are there. One of the interesting things about this lens is that there is no optic rupture. Therefore, in terms of patient comfort, it is probably better than other multifocal IOL designs. My experience thus far is only with the plate-haptic—although it is not really a plate-haptic but a one-piece IOL. I do not like the term *plate-haptic*, because our experience with these IOLs dictates that they are likely to

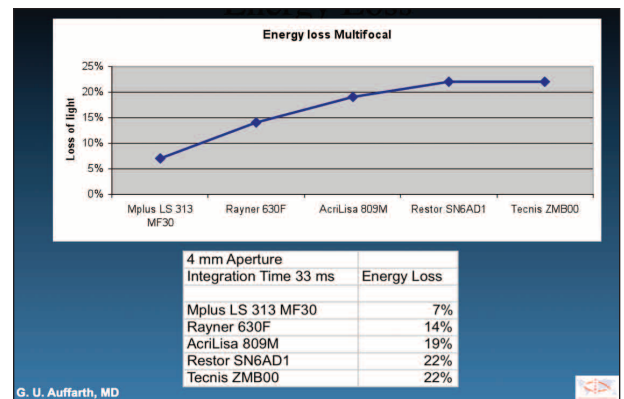


Figure 5. Modular transfer function. Energy loss experienced with the Mplus, Rayner 630F, AT.LISA, ReStor, and Tecnis IOLs.

rotate in the capsular bag, causing various complications. The design of the Mplus is more of a four-haptic IOL, because there are four plates on the IOL. That is the reason why this model is extremely stable in the capsular bag (Figure 2B) and why there are no major complications. In fact, the Mplus is so stable that the IOL is difficult to manipulate, especially when the OVD is removed from the eye.

I have one case that, due to surgical manipulation, the IOL would not stay in the right axis. There was also a traumatic injury of the zonula, and there was evidence of IOL tilt. As a result, the patient lost visual acuity. With the exception of this outlying case, I have been impressed with the quality of vision and the absence of coma after implantation of the Mplus. There is typically no incidence of tilt with this IOL.

Auffarth: Some patient complaints immediately after surgery are not related to the lens. A lot of complaints that we have heard from patients are, in fact, related to surface lubrication. Very often patients describe dry eye symptoms that can also be related to the lens, because there is loss of near vision. But, if you prescribe a good dry eye treatment, then

these kinds of problems go away pretty quickly.

This is an important point, because some surgeons who try a new type of lens are unaware of what kind of symptoms patients will have after implantation. If the patient is describing symptoms that sound like dry eye problems, the surgeon must take measures to address them.

Breyer: This is a very good, and underestimated, point. We routinely advise patients who elect multifocal IOL implantation to use artificial tears as well as steroids and antibiotics after surgery.

TALKING POINT NO. 4: CONTRAST SENSITIVITY

Breyer: With the Mplus, contrast sensitivity is exceptional after surgery, in contrast to other rotationally symmetrical multifocal IOLs. Professor Auffarth has some very interesting images that depict the level of contrast sensitivity that is typical of various multifocal IOL designs.

Auffarth: Figures 3 through 6 can be used to compare contrast sensitivity with the LENTIS Mplus to contrast sensitivity with the M-Flex, the ReZoom (Abbott Medical Optics Inc.), and the Tecnis Multifocal. The first thing that you can see from this series of figures is that the Mplus is similar to the other refractive lenses in that it creates two foci. So even though this lens only has a small segment, it still creates a full image just like the other lenses. Figure 4 shows the rings of the refractive lens, and you can get a feel for how it differs from the diffractive pattern. Our experiment used a standardized set-up so that the same amount of light was projected onto each lens. In theory, the same amount of light should come out from each IOL. What we saw, however, is that much more light came out from the Mplus than from the other IOLs. We have done some other studies on the optical bench to measure the lens power, the modular transfer function, and the energy loss (Figures 5 and 6). Here we determined energy loss was 22% with the Tecnis Multifocal and the Restor Natural, 19% with the AT.LISA, and 14% with the Rayner M-Flex IOL. Energy loss with the Mplus was only 7%; that is one-third the loss of energy that we are used to having with the Tecnis or other diffractive lenses. I think this makes a huge difference with our patients.

Breyer: One of my patients is a restaurant owner, and she is a type A personality. One of the issues she mentioned during the preoperative examination was that she had trouble reading in dim light. She wanted a multifocal IOL, but this was 2 years ago, and at that time I did not have a multifocal lens that would work for her. But after I saw Gerd's images, which depict this gain of light, I implanted the Mplus in her. Even being a very critical and difficult patient, she is absolutely happy with the end result (and asked me why I didn't implant this IOL 2 years ago).

Aramberri: I think that Gerd's pictures correlate with




Figure 6. The above images were all recorded with the same camera integration time (33 ms). Images shown are for far and near at the maximum modular transfer function.

Courtesy of Gerd U. Auffarth, MD

what we have seen in our patients. The absence of decreased visual sensation is what has impressed us most about the Mplus. We no longer hear of patients complaining of foggy vision or not seeing well. I would like to say a word in defense of diffractive lenses, as I have implanted many. Most of my patients who have received a diffractive multifocal IOL are happy, but it was that small number of patients who complained that really annoyed me, and that is what made me turn away from diffractive IOLs. Those patients just weren't as happy as LASIK patients. But with the Mplus, there is improved contrast sensitivity function, and it has brought me joy again in performing IOL surgery.

Granberg: We also transitioned to the Mplus because of this improvement in contrast sensitivity. I operated on one of our optometrists who lives in North Sweden, and he flew into Stockholm for surgery. That evening after surgery, when he was flying home, he was able to read the newspaper in the dim lighting conditions in the cabin. He was so happy with his outcome, and he was -5.00 D.

Carbonara: A few weeks ago, I was looking at Oculentis' Web site and downloaded Professor Auffarth's paper on the contrast sensitivity of the Mplus (Figure 7).¹ I was a bit skeptical, because it seemed to me that this lens was too perfect. I decided to call those of my patients who received the Mplus to check their contrast sensitivity using a Topcon device to measure the contrast sensitivity. All patients demonstrated high levels of contrast sensitivity. Moreover, a frequent response was that they were able to read in bed using only a lamp on the bedside table—and that would never happen with the ReStor, as all those patients complained that they needed more light when they had to read.

Borasio: Optically, there is bound to be a reduction in contrast sensitivity due to the multifocality and the coma that the lens induces. However, this is normally below the patient's subjective threshold, which is what is important for us. Alió recently compared multifocal IOLs with 3.00 D addition to monofocal lenses.² He detected slightly higher contrast sensitivity with the monofocal for near BCVA, but this was below patients' subjective threshold. He did find that

Courtesy of Gerd U. Auffarth, MD

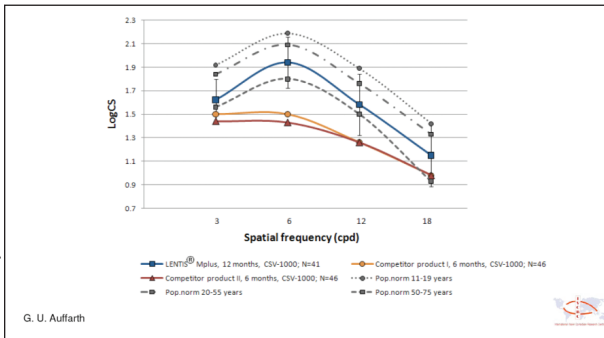


Figure 7. Preliminary 12-month postoperative results: Visual performance with the LENTIS Mplus versus competitor products.

the difference between the IOLs was not significant.

Auffarth: I think that what we have to remember is that diffractive multifocal lenses have been available for 20 years, with a typical energy loss of approximately 20%. If we compare this to 7% (with the Mplus), the difference is not the 14% or 15% we showed in our study—the difference is a 66% less loss of energy. I think if you look at it from this perspective, then you can understand the big difference between this and other multifocal IOLs.

Venter: We found that contrast sensitivity with the Mplus was really similar to that of a monofocal lens. We actually now will use the Mplus on post-LASIK patients, despite some people saying that it will increase the loss of contrast sensitivity. Thus far, we have had excellent results in this population. We just use the coma and place the lens accordingly.

Breyer: Is this after hyperopic LASIK only or do you also implant the Mplus after other laser treatments as well?

Venter: We feel comfortable using this lens in patients who have previously undergone either hyperopic or myopic LASIK.

Breyer: With respect to the coma, correct?

Venter: Yes.

Borasio: Have you seen good results in patients with high hypermetropia?

Venter: Our initial group of 50 patients all had a BCVA of 6/6. We limited it to one laser procedure, and we only implanted the Mplus in patients who had HOAs of 0.50 D or less. So far, all of them have done well. We have not exchanged one lens, so we think this strategy works. Now we are looking at HOAs, especially coma, to see how we can use the benefit of the coma to further improve the outcomes of these post-laser patients.

TALKING POINT NO. 5: COMA

Mertens: Some of my colleagues have told me that there is a lot of coma when you are implanting the Oculentis. But even though we can measure the coma, the patient does not experience any side effects from it.

Venter: Well we only measure the corneal coma, because that is all we really want to know. Any coma that is in the lens will be gone after the lens exchange.

Mertens: Is it important to measure the total coma after the Mplus is implanted in the eye?

Venter: We do not typically measure the total coma—only in patients who have had previous refractive surgery, who have corneal pathology like forme fruste keratoconus, or in those patients who may have HOAs (especially coma) that can influence a better contrast sensitivity outcome.

Breyer: I can add some value here. During a recent lecture I gave in Bavaria, I emphasized that some patients reported seeing a half-moon shape underneath objects. Professor Rentsch also spoke at this meeting and proved our reports using defocus pictures of the IOL's point spread function. However, as we both have experience with our patients, it usually disappears 1 or 2 weeks after implantation, and very few patients are affected by this phenomenon compared with other multifocal IOLs.

Aramberri: I would say that most patients do see that shape after lens implantation. It is obvious for the first few weeks, and perhaps up to 3 months in some cases. Patients have reported that it is most noticeable in spotlights at night. If the lens is placed in the normal way (up/down), all patients will initially notice this inferior comatic effect after implantation. But the eye will undergo a neural adaptation process, and after the first month or so the patient gets used to it and he or she is no longer bothered by it.

Many surgeons worry about the presence of coma; OK, yes, it is there. But it is the same as if I asked you about the visual side effects of the concentric rings within other multifocal IOLs. They are there, too, but we have gotten used to them through the years, and our patients overcome them by neural adaptation.

But it is wise to do a customized treatment in the cornea with a reverse comatic pattern? The challenges with this are (1) how do you calculate the comatic pattern and (2) how do you calculate the spherical equivalent of the total system? I think this is a very tricky and difficult solution. Another (safer) solution is secondary implantation of a reverse optic add-on lens. As far as I know, this has never been tried before. But it could be useful when treating a patient who is still complaining 1 or 2 years after surgery.

Pietrini: Is this common in patients with large pupils?

LENTIS Mplus and LENTIS Mplus Toric

Mertens: No, it can happen in pupils as small as 5.5 mm. Patients were describing the problems they had with night vision, such as seeing double road markings and blurry headlights while driving a car at night. I now implant the lens upside down, and these visual disturbances have disappeared. Naturally, I have been wondering if putting the reading add nasally or temporally would be better. Does anyone know? I only have experience with up and down.

Venter: I have put it temporally, and it worked well.

Mertens: In both eyes?

Venter: Yes. But I have never implanted the reading add nasally, because I am afraid that it will cause dysphotopsias or comatic effects.

Mertens: What are the benefits of implanting the LENTIS Mplus temporally?

Venter: These patients had astigmatism at 90°, so we ended up creating the incision and implanting the lens at 180°. In other patients, the lens was inside the eye with an incorrect astigmatic axis, so we had to rotate the axis to 180°. These patients have done very well.

Mertens: The Mplus Toric can be implanted upside down and the axis remains perfectly aligned. It cannot be implanted with the reading add nasally or temporally.

TALKING POINT NO. 6: LENS MATERIAL

Mertens: Let's discuss the lens material. What are your thoughts of the material design of the Mplus?

Aramberri: I have not worked with this type of lens material in any other multifocal lens designs. Therefore, we had to collect our own results to really judge what this material does and how it behaves over the long-term. In terms of design, I started implanting the C-loop design in September 2009. The rate of Nd:YAG capsulotomy is low, which initially surprised me due to my experience with other hydrophilic lenses. But 1.0 or 1.5 years after implantation, rates are still down, and we are doing less Nd:YAGs than we did with other models.

Mertens: Do you still implant the C-loop?

Aramberri: No, because I had a significant amount of late-onset decentrations. I am now only using the 313.

Mertens: Do you use CTRs with this lens?

Aramberri: Not with the plate-haptic model.

Granberg: We have had significantly lower rates of PCO

after switching to the Mplus. We previously used a mix-and-match strategy with other multifocal lenses, but 20% to 25% of eyes had PCO. Now we are at 5% with the Mplus.

Mertens: Do you see it in the posterior capsule? Because sometimes when we see wrinkles or folds after implantation of standard multifocal IOL, it has a large impact on the patient's visual quality. Have you noticed the same thing with the Mplus?

Granberg: No, I have not noticed any wrinkles after implantation. I have seen some blur in the posterior capsule, but because it does not bother the patient we do not perform Nd:YAG capsulotomy.

Mertens: With other multifocal lens designs, the Nd:YAG capsulotomy is advantageous. Even when you think you have a clear capsule, you do the Nd:YAG capsulotomy and the patient notices a big improvement in the visual quality. But with the LENTIS Mplus, a Nd:YAG is really only required if there is significant PCO. This is a great advantage, as I do not like to do a Nd:YAG capsulotomy within the first 6 months of surgery.

Granberg: We have a 3-month limit, and we do not use CTRs.

Carbonara: I started implanting the Mplus in June 2010, and although I have no great numbers I have not needed to perform Nd:YAG capsulotomy yet. This is different than my experience with other multifocal IOLs, as I frequently used the Nd:YAG laser on these eyes. I recently switched from the C-loop model of the Mplus to the plate-haptic model after hearing others' experiences.

Mertens: I implanted some Mplus lenses with the C-loop design in the beginning, and noticed more stability than with other C-loop designs because it is a thicker lens. But with higher diopters, the lens will still tilt a few degrees. I prefer the plate-haptic model, and actually the company prefers the term *four-point haptic*.

Borasio: I have been implanting the Mplus for approximately 6 months. It is too early to judge PCO rate, but so far I have not had any that required Nd:YAG capsulotomy.

Breyer: I have also seen significantly less PCO since I started implanting the Mplus.

Venter: We have done a significant amount of lenses—in excess of 10,000—and we have found that the PCO rate is not as high as with other multifocal lenses. We never YAG until the patient's dysphotopsias symptoms disappear, because if the symptoms persist we will exchange the lens to a 1.50 D add. This is how we treat all patients who present with ghosting, glare, and halos. In my experience, and I

think this should be the case for any surgeon who is implanting many multifocal IOLs, you must be prepared to exchange the lens if the patient's symptoms persist.

Mertens: I am interested to hear that you exchange the IOL for a lens with a low add, because I used the low add in the beginning and I found that intermediate vision was worse than with the high add.

Venter: True, but the glare is less. Of the 155 patients who underwent lens exchange for the 1.50 D Mplus in the dominant eye and a 3.00 D in the nondominant, their reported incidence of glare at night was less than it was with the 3.00 D in both eyes. The more satisfied the patient was with reading, for which 63% of patients were, the less likely they were to complain. In the majority of patients, we only exchanged the dominant eye to a 1.50 D. That alleviated symptoms to such an extent that they were satisfied with their vision. We have exchanged the 3.00 D Mplus for the 1.50 D Mplus in about 26 eyes, and in two cases we did the exchange to 1.50 D add bilaterally. All of the others we only exchanged the 3.00 D for the 1.50 D in one eye.

Mertens: Well 26 of 10,000 eyes is a small percentage. My Nd:YAG capsulotomy rate is also very low.

Moore: I initially treated 50 patients with 1.50 D in the dominant and 3.00 D in the nondominant eye. Overall, these patients had earlier adaptation to the IOLs in relation to complaints of dysphotopsias; however, more patients complained of reduced reading ability compared to binocular 3.00 D treatments. My current practice is inferior near adds with bilateral 3.00 D.

Auffarth: I have had similar results. Even in our initial study, only occasionally did a patient require Nd:YAG laser. So the PCO rate seems to be very good with the Mplus.

TALKING POINT NO. 7: CTRs

Mertens: Are any of you afraid that, if you do not use a CTR, that the lens will eventually rotate?

Aramberri: I have stopped implanting a CTR now that I have transitioned to the 313 platform, and I have had no problems with centration at 1 year.

Moore: Other than for pseudoexfoliation, I do not use CTRs with the new 313 platform.

Granberg: We have implanted the Mplus in approximately 2,000 eyes. Before this, we were not in the practice of using CTRs, and we have not even thought about it with the Mplus, because there have been no problems with centration. This is only with 6-month follow-up, which is too early, but we have a big number of patients to draw from.

Breyer: I don't think you have to implant a CTR, but in some cases it may be advantageous, not only for the stability of the IOL. Especially in younger clear lens extraction patients, I look at it as a safety investment for the future.

Venter: In 2009, we started implanting the C-loop design. At the end of that year, the lens was either tilted or displaced in 26 of 5,000 eyes. That is close to 0.5%. We managed all of these patients by removing the C-loop and implanting the four-point haptic lens. We were able to remove the C-loop within 18 months without much of a problem. We have not used any CTRs. One year ago we started using the 313, and we have not seen any tilting of the lens.

TALKING POINT NO. 8: OUTCOMES

Mertens: What are your patients' visual results at distance, near, and intermediate? I will start. (See *Refractive Lens Exchange With Customized Bifocal Toric IOL*.)

Aramberri: In general, for far and near vision, this lens is brilliant compared with other multifocal lenses. The point I stress to patients is the quantity of near vision. I tell my patients that they can expect good newspaper-reading ability but they might need some other kind of correction for near for other small tasks. By using glasses, though, they will have the perfect ability for small handwork. With this conditioning preoperatively, patients are extremely happy, and their expectations are met after surgery.

Granberg: I have had the same experience, Jaime. I believe in the strategy of under-promise and over-deliver. I will tell my patients that 80% will be spectacle free for daytime work. In low-light conditions and at the computer, I tell them that they will need spectacles.

Carbonara: I remind patients that there is a good chance for spectacle independence, because I am sure the postoperative results will be superb. Up to now, I have not had any refractive surprises.

Borasio: I analyzed my outcomes just before coming here, and this is for 20 eyes. There is total spectacle independence in 28% of my patients; 22% need a near addition of 1.00 D, 17% need about 1.25 D, and 17% need a 2.00 D near add. In terms of distance UCVA, 56% of eyes achieved 6/6 or better and 89% achieved 6/9 or better. Plotting the astigmatism before and after the operation on double-angle polar plots has shown excellent reduction of the astigmatism both after Mplus and Mplus toric IOL implantation (Figure 8).

Mertens: Did you specifically ask for what kind of near-vision tasks patients needed their reading glasses?

Borasio: Yes. In total, 94% of patients achieved N4, which is smaller than newspaper print.

LENTIS Mplus and LENTIS Mplus Toric

Mertens: So you still have a relatively high percentage of patients using reading glasses.

Borasio: Only for certain tasks. They are happy 90% of the time during the day without additional correction. Then they may need a small addition for certain tasks, such as reading a book for a long time or reading in dim light conditions. What makes patients happy with the Mplus is the intermediate vision. Our lives are mainly at the intermediate distance, so this is extremely important to patients.

Venter: We have data for a fairly large number of patients. We promise patients that they will have good newspaper vision. When we look at our patients' reading ability, 95% achieve N8 or better. In terms of distance UCVA, 83% are 20/20 or better. Intermediate vision is good with the lens as well, so we only have a small number of patients who might need a 1.00 or 1.50 D add. We obtained a questionnaire on quality of vision (FDA format) from 1,000 patients at 1 year with the 3.00 D add Mplus, and 94% of patients stated that they never wear any glasses.

Moore: In my initial experience using 1.50 and 3.00 D Mplus IOLs, the mean (\pm SD) logMAR UCVA was 0.04 (\pm 0.25), contrast sensitivity was 1.57 (\pm 0.13), near vision was M0.75 (\pm 0.33) at 32 cm and M0.90 (\pm 0.27) at 66 cm, and reading speed was 161.74 words/min (0.4 logRAD at 32 cm). Patients were still complaining slightly, similar to what Dr. Borasio mentioned, that some of their reading was not as good. I started implanting the 3.00 D in both eyes and where necessary aimed for -0.40 D in the nondominant eye, based upon early visual results in the first eye treated (dominant eye). I have found that I have been able to improve subjective near vision results with this technique.

Pietrini: One of the strengths of this lens is certainly the level of intermediate vision it provides. Even though near vision is sometimes insufficient, patients (especially those with high myopia) should only need a small add for special tasks. In some cases, the only reason a near add is needed is because the patient is demanding. Concerning far visual acuity, I think that depending on the patients' needs, we can fine-tune things to favor distance vision. But if we want to have good vision, we should target smaller myopic ranges.

Mertens: I have had a similar experience. The most difficult patients to satisfy are those with -1.25 to -1.50 D of myopia, because they are used to reading small print without glasses or contact lenses. We must be especially careful when counseling these patients before surgery. I tell them that they will be spectacle free for 80% of their daily activities; this is on the safe side. Indeed some of them will need to use 1.00 D add for some tasks, but some won't need any add.

Auffarth: I tell patients that there is a difference between

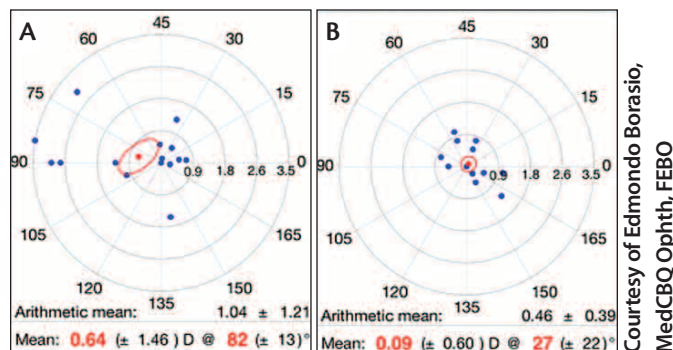


Figure 8. (A) Pre and (B) postoperative astigmatism distribution after Mplus and Mplus Toric IOLs; calculated with the Eye Pro 2011. Arithmetic and summated vector means are also reported.

Courtesy of Edmondo Borasio, MedCBQ Ophth, FEBO

spectacle independence and spectacle freedom. Spectacle independence means that they will always achieve some type of independence from spectacles, whereas spectacle freedom means that they will never need spectacles. I tell patients that they may achieve 100% of the visual acuity that they like but only 90% of the day will they be independent from spectacles. But there are some infamous patients, like engineers for example, who expect spectacle freedom. In general, these patients won't do well with multifocal lenses. If they understand the difference between spectacle independence and spectacle freedom, then I think they are on the right track.

Breyer: The wording that we use with our patients is vital. I would like to go back to those patients we were referring to earlier who have double vision after multifocal lens implantation. If a patient comes back several months after surgery complaining of double vision, I will use the following explanation: "It is good you are having this double vision; otherwise, the IOL wouldn't be working properly." It is amazing what this one sentence does to change the patient's perspective. They come back 2 or 3 months later and they are content with their vision (Figure 9).

Auffarth: You can also tell the patient that it is just a matter of neural adaptation and after 3 to 6 months these double images will resolve themselves.

Mertens: I tell my patients the same thing, Gerd. I tell them that there are two images in the eye, one for far and one for near. When looking at an object at a distance, near focus is blurry, and the brain has to learn to get rid of the near focus. It is the other way around when reading. It is important that patients understand this concept, and after a couple months most of my patients do not mention these double vision symptoms anymore. Like Gerd said, the brain is a powerful thing.

TALKING POINT NO. 9: STRENGTHS AND WEAKNESSES

Mertens: Moving on, let's discuss the strengths and weak-

REFRACTIVE LENS EXCHANGE WITH CUSTOMIZED BIFOCAL TORIC IOL

By Erik L. Mertens, MD, FEBOphth

In my experience, not only does the LENTIS Mplus IOL (Oculentis GmbH) score very high on the patient satisfaction scale, but it also has a much lower incidence of glare and halos compared with other multifocal IOLs. Additionally, stability in the capsular bag is excellent, making this lens a top choice in my clinic.

My most recent results include data for 50 eyes implanted with the Mplus. Preoperatively, patients' mean spherical equivalent was -0.34 ± 4.17 D (range, -13.75 to 6.75 D), with a mean sphere and cylinder of 0.58 ± 4.01 D (range, -11.75 to 7.00 D) and -1.84 ± 1.15 D (range, -5.50 to -1.00 D), respectively.

Patients ranged in age from 47 to 75 years, and the follow-up rate was 100%. The mean improvements in spherical equivalent, sphere, and cylinder at 1 month were 0.07 ± 2.27 D (range, -0.38 to 1.00 D), 0.13 ± 0.32 D (range, 0.00 to 1.00 D), and -0.12 ± 0.36 D (range, -1.25 to 0.00 D), respectively. Additionally, 22% of eyes gained 1 line of visual acuity, 10% gained 2 lines, and 4% gained more than 2 lines at 1 month. The visual acuity remained unchanged in 47% of eyes at 1 month. In terms of distance-corrected intermediate visual acuity, 100% of patients were J1 or better at 1 month. For cumulative distance-corrected near visual acuity, 100% of patients were J4 or better at 1 month, 86% were J2 or better, and 33% were J1 or better.

I also have results for 24 eyes at 12 months. In this group, visual acuity remained unchanged in 58% of patients, while 29% gained 1 line and 4% gained 2 lines. All patients remained at J1 for distance-corrected intermediate visual acuity, and 100% remained J4 or better for distance-corrected cumulative near visual acuity. There was a slight improvement in the number of patients who were J2 or better (88% vs 86%) and a significant increase in the number of patients who were J1 or better (54% vs 33%).

There was a slight decrease in near vision compared with other multifocal lens designs, and 14% of patients reported a shadow when reading. I believe that tilt can cause this side effect; however, rotational stability is excellent at 1 month as well as at 12 months.

In conclusion, in my cohort of 50 eyes implanted with the Mplus, patients had good distance, intermediate, and near vision. The rate of glare and halos is infrequent, and overall my patients have been happy with this lens.

nesses of the Mplus Toric technology. Are there areas that need improvement?

Aramberri: I have found that most of the lens' features are strengths. The Mplus Toric has seduced me as a multifocal toric because of its total correction zones and the excellent postoperative results. I think we all share this perception, and in fact I have found that the higher the cylinder, the happier the patient is after surgery. This is logical, because we can correct two big problems for them, aberrations and astigmatism. If I had to list two of the most positive aspects of the Mplus Toric, I would say that the first is that this lens provides a customized cylinder. I really like to know that all of the cylinder in the cornea will be compensated for. I no longer need to round calculations, and therefore the correction is more precise. Additionally, the postoperative calculations really work well. The lens is correctly manufactured, and it provides exactly what it promises. I think that is great. This is the first point.

The second point is that centration is excellent. When there are only two marks in the optic for alignment, as many other lenses have, centration can be really tricky, as it is hard to know if you are on axis in the operating room and under the microscope. But with more reference marks it is easier to centrate the lens. With the Mplus, there are two horizontal lines, one asymmetric line, and the optic marks. I also make a point to mark the vertical lines in these eyes preoperatively. Therefore, I have four reference points, and I also put them on the toric lens at the slit lamp. Once I have the patient in position, I implant the lens and rotate it into position. I have so many references that I feel that centration is always perfect.

Granberg: The toric lens is just as easy to implant as the standard Mplus. I make one marking at the 6-o'clock position, and I feel that is safe enough to achieve perfect centration. Additionally, the option for customized cylinder is nice to have. The only thing that is a drawback is that you have

Courtesy of Detlev Breyer, MD

How good is your vision...

Near	Handwork	2.1
	Cooking	1.3
Far	Watching TV	1.3
	Driving a car	1.1
Light sensations	Day	1.1
	Night	2.0
	Straylight	6/17
Intermediate	Halo	5/17
	Near	4/17
	Far	2/17

1= very good to 6= bad

A

Quality of vision without glasses?	1.6	
How often do you wear glasses?	1.4	
How often glasses for far?	1.1	
How often reading glasses?	1.6	
How good is your vision reading	Very small print	2.6
	Newspaper	2.1
	Traffic signs	1.1

⇒ Grading: 1 = never or very good to 5 = always or very bad

B

Figure 9. (A) Patient questionnaire at 1 month postoperative. (B) Patient questionnaire at 3 months postoperative.

LENTIS Mplus and LENTIS Mplus Toric

Courtesy of Dominique Pietrini, MD

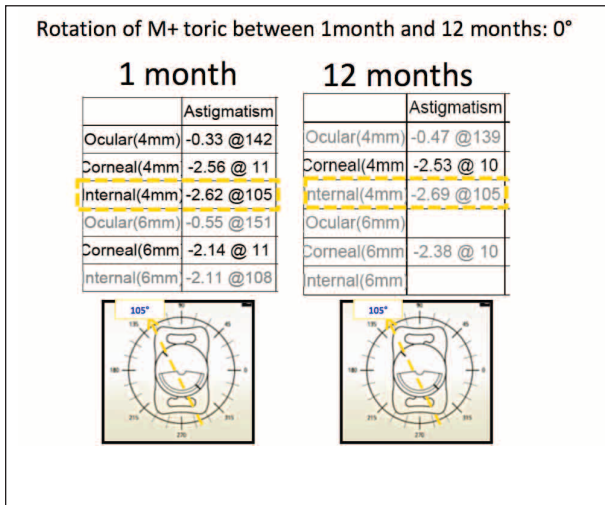


Figure 10. One month and 1 year measurements of the internal wavefront show that the IOL is perfectly stable.

Courtesy of Dominique Pietrini, MD

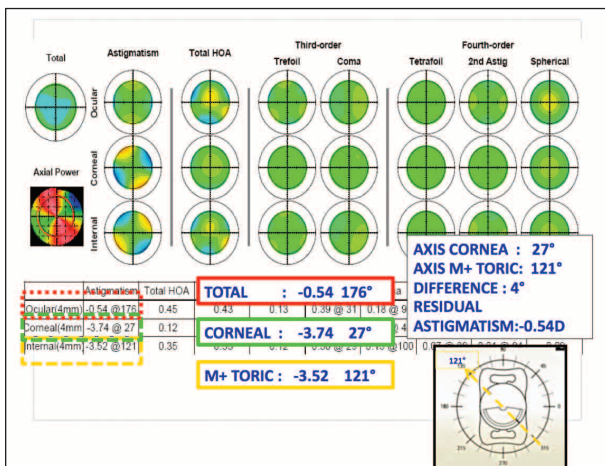


Figure 12. The cylinder of the IOL was positioned in the eye at 121° to compensate for -3.74 D of preoperative astigmatism. Here, pre- and postoperative corneal astigmatism are shown.

to wait 2 or 3 weeks to get it. If you are implanting a lens with customized cylinder in a good number of your patients, that is a lot of logistics.

Carbonara: Another thing that my patients appreciate is that there is no jump between the near and far vision with the Mplus as well as the Mplus Toric.

But what I would like to talk about is biometry. In contrast to my experience with some competitor lenses, Oculentis lets me calculate the power of the Mplus lens to be implanted. After that, the software does the calculation for the toric correction. With other IOL models, I had to send all the collected data to the company, and they did the calculation directly. I never knew how they did it, nor which formula they used and, in the end, I could have been responsible for their mistakes. This is another reason that I like the Mplus Toric. I like the fact that, with Oculentis, I can calculate the power of the IOL and they do the calculation

Courtesy of Dominique Pietrini, MD

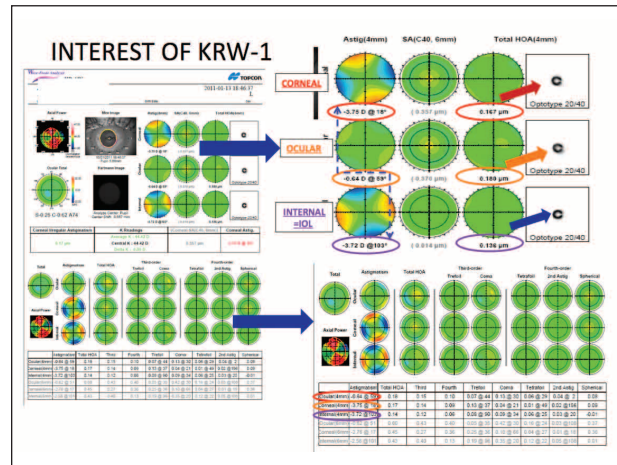


Figure 11. The IOL was implanted in the eye at 13° to compensate for -3.75 D of corneal astigmatism. Here, pre- and postoperative corneal astigmatism are shown.

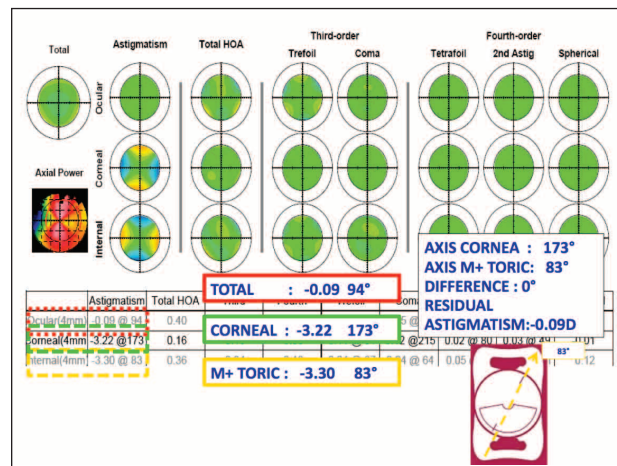


Figure 13. After implantation of the Mplus in this eye, the residual astigmatism was only 0.09 D.

only for the toric power of the IOL.

Borasio: I like the four-point haptic design, as it is easy to implant. In one case, the distal haptic of the C-loop design got stuck between the plunger and the cartridge, probably because I hadn't assembled it correctly. Looking at its position inside the cartridge, I do not think I advanced it enough, and it became stuck. To achieve good alignment, I always mark the horizontal meridian at the slit lamp before taking the patient to the operating theater.

Venter: The lens with the four-point haptic is easy to implant. Additionally, because the astigmatism is prealigned, you can leave the lens at 90°, eliminating the need to move the lens anywhere inside the capsular bag. Another great thing is the stability of the Mplus. We have looked at the 6-month results in 350 eyes, and all of them were within 10° of the target.

Breyer: Another advantage of the Mplus is the fact that

Courtesy of Dominique Pietrini, MD

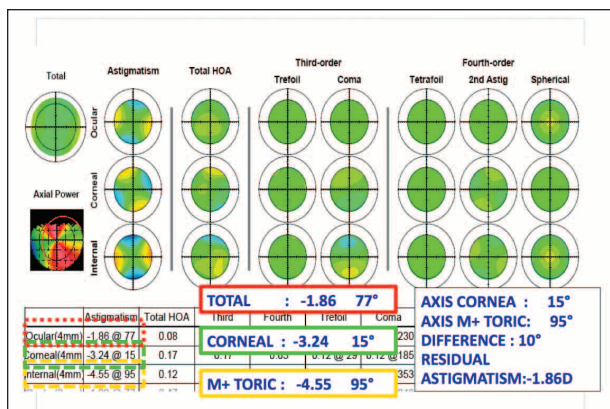


Figure 14. With a 10° misalignment of the IOL, the patient had -1.86 D of residual astigmatism.

it can be implanted through an absolutely astigmatism neutral incision of 1.5 mm. You do not have to discuss surgically induced astigmatism with the patient. Surgery becomes more precise and easier to plan, which is especially important for toric multifocal IOL. That is when art becomes science.

TALKING POINT NO. 10: STABILITY

Mertens: How do you measure stability?

Venter: We measured refraction, and we dilated the pupil and checked the axis of astigmatism. Then, at 6 months, we checked the refraction, which we have from 1 week, 1 month, 3 months, and 6 months postoperatively. These were all within our intended refraction. Stability is a real important aspect for this toric lens and one of the reasons it works so well in the eye.

Breyer: One great tool is the KR-1W aberrometer, as it simultaneously measures to total, corneal, and internal astigmatism and aberrations.

Mertens: Dominique, I understand that you have some marvelous pictures depicting the stability of this lens. Would you like to share those with us?

Pietrini: Figure 10 does indeed showcase the stability of the Mplus. In most cases where stability is an issue, the problem stems from the patient or the surgeon, not the lens. Complications can occur when we do not perform perfect surgery.

We also wanted to determine the IOL's stability and the right positioning, so we looked at the K1 values with topography and simultaneously with the wavefront analyzer. All these visuals were made with the KR-1W analyzer. It is really interesting in the case of toric lens implantation, because you have the topographic map and the topographic axis, but you also have the wavefront, which can be composed in the cornea or in the IOL itself. So if we look at Figure 11, we can see that the patient has -3.75 D of corneal astigmatism

Courtesy of Dominique Pietrini, MD

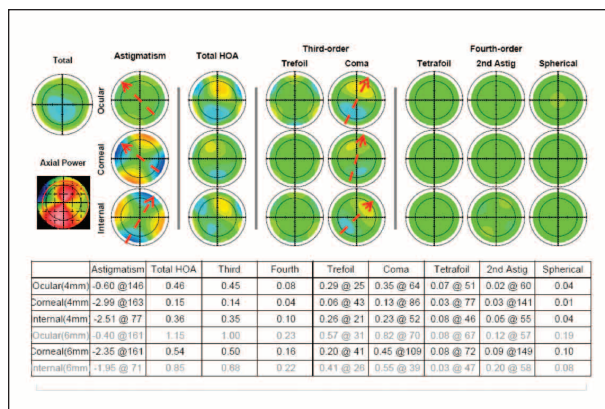


Figure 15. Even though this IOL was misaligned, there is still no presence of coma postoperatively.

preoperatively at 18°. After surgery, the patient has -0.60 D of residual astigmatism at 60°, which is then corrected with refraction. The IOL itself is -3.72 D at 103°. The axis of implantation was 13° instead of 18°.

In Figure 12, the patient had -3.74 D of corneal astigmatism at 27°, and we positioned the Mplus IOL in the eye at 121°. The patient had -0.50 D of residual astigmatism after surgery. The difference of axis is only 4° in this case, and there was a small amount of residual astigmatism.

These results are extremely interesting, because you can analyze the lens itself and you can ensure that, if you place the lens in the right axis, you will have good results.

Mertens: For every degree of misalignment, you lose 3%.

Pietrini: When you implant the lens exactly on the axis, there should be no residual astigmatism. In one case (Figure 13), the difference was 0°, and there was only 0.09 D of residual astigmatism. In this last case I would like to share, the patient had high astigmatism preoperatively, and the residual astigmatism after IOL implantation was -1.86 D because of a 10° misalignment (Figure 14). When we analyzed the result, we were careful not to incriminate the surgery or the patient. We tried to evaluate the coma, but even in cases of misalignment, there is almost no coma (Figure 15).

Mertens: Thank you for sharing these case studies with us, Dominique. We are able to learn a lot from them, just as we were able to learn a lot by sharing our thoughts and our experience with the LENTIS Mplus. I think this was a great discussion, and I thank you all for attending. ■

1. www.oculentis.com/profilentismplus.html#. Accessed January 3, 2012.
 2. Alió JL, Pínero DP, Plaza-Puche AB, Chan MJ. Visual outcomes and optical performance of a monofocal intraocular lens. *J Cataract Refract Surg.* 2011;37(2):241-250.

Oculentis GmbH
Competency in Intraocular Surgery
Am Borsigturm 58
13507 Berlin, Germany
Tel: +49 30 43 09 55-0
Fax: +49 30 43 09 55-11
E-mail: berlin@oculentis.com
Web: www.oculentis.com

Cataract & Refractive Surgery
EUROPE **TODAY**